Equine Veterinary Journal

Equine Veterinary Journal ISSN 0425-1644
DOI: 10.1111/evj.12813

Abnormal locomotor muscle recruitment activity is present in horses with shivering and Purkinje cell distal axonopathy

J. E. AMAN[†]*, S. J. VALBERG[‡], N. ELANGOVAN[§], A. NICHOLSON[¶], S. S. LEWIS[¶] and J. KONCZAK[§]

[†]Department of Neurology, University of Minnesota, Minneapolis, Minnesota, USA
[‡]Department of Large Animal Clinical Sciences, College of Veterinary Medicine, Michigan State University, East Lansing, Michigan, USA
[§]School of Kinesiology, University of Minnesota, Minneapolis, Minnesota, USA
[¶]Department of Veterinary Population Medicine, College of Veterinary Medicine, University of Minnesota, St. Paul, Minnesota, USA.

*Correspondence email: aman0038@umn.edu; Received: 22.03.17; Accepted: 10.01.18

Summary

Background: Cerebellar Purkinje cell axonal degeneration has been identified in horses with shivering but its relationship with abnormal hindlimb movement has not been elucidated.
Objectives: To characterise surface electromyographic (sEMG) hindlimb muscle activity in horses with shivering, correlate with clinical scores and examine horses for Purkinje axonal degeneration.
Study design: Descriptive controlled clinical study.
Methods: The hindlimb of seven shivering and six control draught horses were clinically scored. Biceps femoris (BF), vastus lateralis (VL), tensor fasciae latae and extensor digitorum longus were recorded via sEMG during forward/backward walking and trotting. Integrated (iEMG) and peak EMG activity were compared between groups and correlated with clinical locomotor exam scores. Sections of the deep cerebellar nuclei (DCN) of six of the seven shivering horses were examined with calbindin immunohistochemistry.
Results: In control horses, backward walking resembled forward walking (right hindlimb peak EMG: backward: 47.5 ± 21.9%, forward: 36.9 ± 15.7%) but displayed significantly higher amplitudes during trotting (76.1 ± 3.4%). However, in shivering horses, backward walking was significantly different from forward (backward: 88.5 ± 21.5%, forward: 49.2 ± 8.9%), and resembled activity during trotting (81.4 ± 4.8%). Specific to backward walking, mean sEMG amplitude fell outside two standard deviations of mean control sEMG for ≥25% of the stride in the BF for all seven and the VL for six of the seven shivering horses. Locomotor exam scores were correlated with peak EMG (r = 0.87) and iEMG (r = 0.87). Calbindin-positive spheroids were present in Purkinje axons in DCN of all shivering horses examined.
Main limitations: The neuropathological examination focused specifically on the DCN and, therefore, we cannot fully exclude additional lesions that may have influenced abnormal sEMG findings in shivering horses.
Conclusion: Shivering is characterised by abnormally elevated muscle recruitment particularly in BF and VL muscles during backward walking and associated with selective Purkinje cell distal axonal degeneration.

Keywords: horse; shivers; cerebellum; electromyography; gait

Abbreviations

BF	Biceps femoris
DCN	Deep cerebellar nuclei
HE	Haematoxylin and eosin
EDL	Extensor digitorum longus
iEMG	Integrated electromyography
MVC	Maximum voluntary contraction
sEMG	Surface electromyography
VL	Vastus lateralis
TFL	Tensor fasciae latae

Introduction

Equine shivering is a neuromuscular disease with characteristic signs of intermittent muscle fasciculations or 'shivering' of the hindlimb muscles that is elicited by specific locomotor movements [1,2]. Walking backward often results in either a hyperflexed abducted hindlimb or a rigidly extended hindlimb, whereas forward gaits often appear normal [3]. Hindlimb hyperflexion in horses with advanced shivering, however, can occur with initiation of forward walking or directional changes [3,4]. Manually lifting and flexing of the hindlimbs also triggers shivering, rendering the horse unable to hold up the limb for cleaning or trimming the hind hooves [3]. The connection between abnormal limb positions (e.g. hindlimb hyperflexion) and muscle activity in horses with shivering has not been established. Surface electromyography (sEMG) provides a means to assess muscle recruitment activity and patterns and has been used reliably on hindlimb muscles in horses [5–7]. The activity and force generated by recorded muscles can be evaluated by assessing the activation and quiescence of muscle sEMG patterns across a stride and subsequently calculating peak EMG output and total activity of a muscle over a defined period of time, or integrated (i)EMG. Thus, sEMG is an ideal technique to determine if motor unit recruitment of hindlimb flexor and extensor muscles is abnormal during locomotion in shivering horses.

Recent evidence suggests that shivering is associated with a focal lesion in the cerebellum [8]. Neuropathological evaluation of the entire central nervous system of one Thoroughbred and four Warmblood horses with shivering identified selective degeneration of distal Purkinje cell axons in the lateral deep cerebellar nuclei (DCN) [8]. Calbindin staining, which identifies Purkinje cells, highlighted the axonal spheroids. Although rare, axonal spheroids have been found in control horses. However, shivering horses exhibited greater than an 80-fold increase in the number of axonal spheroids compared with controls [8]. Apart from lesions in the DCN, no other pathological lesions within the muscular, central and peripheral nervous systems specific to horses with shivering were identified. Abnormal motor unit recruitment in shivering is attributed to interruption of inhibitory signals from Purkinje cells that synapse in the DCN upon motor efferents which project to regions of the motor cortex that control limb and axial muscle activation patterns [9]. A link needs to be established between lesions in the DCN of horses with shivering and abnormal hindlimb muscle recruitment patterns.

The purpose of the current study was to characterise hindlimb muscle recruitment activity in horses with shivering, correlate clinical locomotor

exam scores with muscle activity and examine shivering draught horses for DCN Purkinje cell axonopathy.

Materials and methods

Horses

Seven geldings with a clinical diagnosis of shivering (five Belgian Draught, one Clydesdale and one Shire) were donated to the University of Minnesota. Average mass of the horses was 846 ± 90 (s.d.) kg and average age was 9 ± 6 years. The initial diagnosis of shivering was based on reluctance to walk backwards, reluctance to consistently hold the hindlimb flexed when manually lifted by the handler and in some cases intermittent hyperflexion of the hindlimb when initiating forward locomotion. Data were also collected from six control horses (two Belgian Draught geldings, two Clydesdale geldings, one Shire gelding and one Percheron mare) that were provided for examination by their owners. Average mass of the horses was 861 ± 153 kg and average age was 8 ± 3 years. No evidence of a hindlimb gait abnormality was observed in any of the control horses.

Electromyography

EMG set-up: Four muscles on both the right and left hindlimbs were monitored via sEMG: biceps femoris (BF), vastus lateralis (VL), tensor fasciae latae (TFL) and extensor digitorum longus (EDL) (Fig 1). Muscles were selected based on their function: abducting and extending the hip and stifle (anterior BF) extension of digits and flexing the hock (EDL), extending the stifle (VL) and flexing the hip and extending the stifle (TFL). Electrogoniometers were placed around the right and left fetlock joints to capture temporal parameters of gait and to associate muscle activation patterns with specific phases of the stride cycle (Fig 1b). Further details of sEMG set-up can be found in Supplementary Item 1.

Data acquisition protocol: Each electrode and goniometer lead was attached to an 8-channel data log unit[a] that stored the data for later analysis. Raw EMG signals were collected at a sampling frequency of 1 kHz. Each horse completed five movement patterns in a single continuously recorded trial – standing still, lifting and flexing the hindlimb, walking backward (referred to as 'backward'), walking forward (referred to as 'forward') and trotting forward (referred to as 'trotting'). A video recording was made during each locomotor exam. Initially, the horse stood still for a period of 10 s in order to collect baseline sEMG activity, and then each hindlimb was lifted and flexed once by a handler and held for a period of 5 s. Next, horses were walked backward for 12 total strides (right and left hindlimb combined). The horse was then walked forward for a total of about 20 strides and finally trotted for a total of about 20 strides. In each trial two muscles were recorded simultaneously on each hindlimb (set #1: BF/VL – right and left hindlimb, set #2: TFL/EDL – right and left hindlimb), along with recording from a goniometer on each hind fetlock joint. Each horse completed a minimum of four trials, two consecutive trials for muscle set #1 followed by two consecutive trials for muscle set #2. Each horse, therefore, completed a total of 8 leg lifts, 48 backward strides, 80 forward strides and 80 trotting strides for the entire data collection (4 leg lifts, 24 backward, 40 forward and 40 trotting strides per hindlimb – half for muscle set #1 and half for muscle set #2).

EMG measurements and analysis: sEMG recordings were filtered and treated as described in Del Luca *et al.* [10]. Ten total strides for forward walking and trotting and six strides for backward walking of each hindlimb were extracted from the data (five consecutive forward/trotting and three consecutive backward strides from each trial). Maximum naturally induced contraction for each muscle was estimated as maximum contraction during trotting by determining the average of 10 peak amplitudes of the trotting strides [5]. Trotting was selected because it is known to have the highest amount of EMG activity of the three tested gaits [6,7]. Ensembles of all extracted strides (hoof strike to subsequent hoof strike) were produced and the mean and s.d. of normalised sEMG (normalised to max sEMG during trotting) were calculated across normalised stride cycle (normalised to 0–100% of stride time) during forward, backward and trotting. Peak EMG and integrated EMG (iEMG) were then calculated for all muscles in each gait.

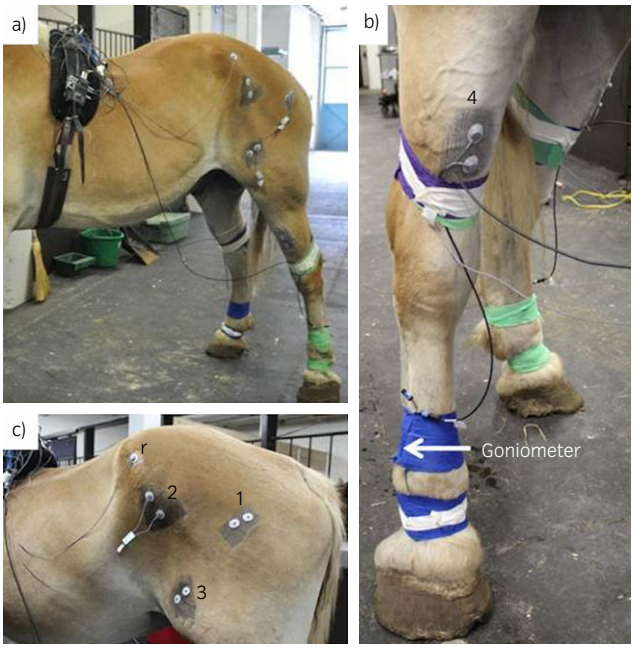

Fig 1: a) Overview of a complete set-up, including the data logger affixed to the left side of the surcingle with attached leads to sEMG electrodes and goniometers. b) Placement of an electrogoniometer across the fetlock joint (white arrow) underneath elastic wrap to hold it in place and sEMG electrodes attached to the extensor digitorum longus (4). c) Electrode placement of the biceps femoris (1), tensor fasciae latae (2), vastus lateralis (3) and reference electrode (r).

Due to the markedly abnormal motor unit recruitment activity in shivering horses, onset and offset of sEMG was often indeterminable. Therefore, the sEMG activity of the entire stride was classified as abnormal if the mean sEMG for a shivering horse fell outside of two s.d. of mean sEMG activity of the control horses for 25% or more of the stride cycle. Further details of sEMG set-up, measurement and analysis can be found in Supplementary Item 1.

Neurological assessment: A complete equine neurological examination including evaluation of mentation, cranial nerve function and evidence of intention tremor, proprioceptive deficits, and assessment of muscle mass was performed for shivering and control horses by a veterinarian board certified in large animal internal medicine (S.J.V.).

Clinical locomotor score: One experienced examiner (S.J.V.) that was blinded to the results of the sEMG analysis evaluated videos of all horses performing the locomotor exam. The scoring system used was; 0 = normal, 1 = intermittently abnormal but mild, 2 = intermittently abnormal and readily apparent, 3 = abnormal and consistently apparent. Picking up the limb, forward walking, backward walking and trotting of each horse was scored for 1) reluctance to perform the procedure, 2) the degree of coordination of the movement between fore- and hindlimbs and 3) the presence of hyperextension or hyperflexion for each hindlimb (maximum score = 12). For the standing phase, horses were scored for 1) reluctance to stand still and each hindlimb was scored for spontaneous hyperflexion (maximum score = 9). The score for each phase/gait of the locomotor examination was summed to produce a total locomotor exam score for each horse. A full lameness examination was not performed on the horses as no lameness was apparent during the trot.

Neuropathology

After completion of the sEMG data collection and on separate days, six of the seven shivering horses were subjected to euthanasia by i.v.

administration of a barbiturate and immediately transported to the necropsy facility. Within 2 h of euthanasia, the brain was removed and placed in 20% buffered formalin for a minimum of 7 days. Based on the results of a recent detailed neuropathological study of shivering which found that the underlying neuropathology was restricted to the DCN and no other central or peripheral nervous system involvement [8], we here limited our investigation to the regions of the left and right DCN. Paraffin embedded sections containing the lateral DCN were stained with haematoxylin and eosin (HE) and immunohistochemical staining for calbindin was performed as previously described [8]. Calbindin is a Purkinje cell-specific protein in the cerebellum and has been widely used in cerebellar Purkinje cell studies [11]. The number of axonal swellings (spheroids) was counted in HE and calbindin stains for both left and right lateral DCN. No control horses were subjected to euthanasia for this study and, therefore, not included in this part of the study.

Data analysis

To analyse the overall effect of shivering on total muscle activity during gait, both peak EMG and iEMG values were averaged across all recorded muscles, for each hindlimb, for each gait condition, giving each horse a total iEMG value and total peak EMG value per hindlimb per gait. This was done in order to capture the overall effect of shivering on muscle activity, regardless of which muscles were more/less effected. Values for shivering horses were then compared against control horses, analysing right and left hindlimb separately. After performing a Shapiro–Wilk normality test on data for each hindlimb, the effect of shivering on peak and iEMG activity during each type of gait was evaluated using, if normally distributed, a two-way ANOVA and Bonferroni pairwise comparison or for non-normally distributed data, a Kruskal–Wallis test and Dunn's multiple comparison. Total clinical locomotor examination scores were correlated with total iEMG and total peak EMG activity during backward walking using a Spearman rank correlation. Next, in order to evaluate individual muscle activity, a Mann–Whitney *U* test was used to compare peak and iEMG activity within all recorded muscle groups of shivering vs. control horses for each hindlimb, for each gait. A P value of $\leq$0.05 was taken as statistically significant. Statistical analyses were performed using GraphPad[b]. Values are expressed as mean and s.d. or median (range).

Results

Clinical assessment

Neurological exam: The control horses and five of seven shivering horses were in good general health and had normal muscle mass and strength. Generalised loss of muscle mass, lordosis and a stretched out base wide hindlimb stance at rest were identified in two shivering horses (S4, S7) (Fig 1). No head tremors, truncal sway, proprioceptive ataxia or proprioceptive deficits were noted in any horses and mentation and cranial nerve function appeared normal.

Electromyography

Muscle activation patterns: An example of the marked difference between shivering and control horse sEMG recordings during backward, forward walking and trotting is provided in Figure 2. The marked differences in individual shivering horses in mean EMG ensembles for each muscle of the right leg during forward and backward walking is apparent when overlaid on group sEMG ensembles for control horses (Fig 3). During backward walking, the mean normalised sEMG activity of the BF was considered abnormal (outside 2 s.d. of mean control sEMG for $\geq$25% of the stride) in all seven shivering horses while mean sEMG activity of the VL was abnormal in six of the seven shivering horses. During forward walking, sEMG activity of the BF was abnormal in five of the seven shivering horses and sEMG activity of the VL was abnormal in two of the seven shivering horses. The mean sEMG activity of the TFL and EDL was considered abnormal during backward walking in three of the six and four of the six shivering horses, respectively, (no data for one horse due to technical difficulties) and during forward walking in four of the seven and five of the seven horses respectively (Fig 3). Supplementary Item 2 shows group mean sEMG ensembles of each muscle for control and shivering horses during backward walking.

Peak and iEMG activity with gait: In control horses, there was no difference in mean normalised peak EMG and iEMG for either left or right hindlimb between forward and backward walking (Table 1). Mean normalised peak EMG and iEMG for muscles of the right hindlimb and iEMG for muscles of the left hindlimb were significantly higher during trotting than during backward or forward in control horses (Table 1). In contrast, in shivering horses, peak and iEMG activity was significantly higher when walking backward compared to forward (Table 1). Interestingly, there was no difference in mean normalised peak EMG and iEMG between trotting and walking backward in either the left or right hindlimb of shivering horses (Table 1). When comparing data from individual muscles of the right hindlimb, the BF and VL muscles of shivering horses had significantly higher mean peak (BF $P = 0.0012$, VL $P = 0.014$) (Fig 4) and iEMG (BF $P = 0.0012$, VL $P = 0.0047$) activity compared with control horses during backward walking. During forward walking, peak EMG of BF ($P = 0.035$) (Fig 4) and iEMG activity of EDL ($P = 0.035$) were higher in shivering horses compared with control horses. The only significant difference between individual muscles of the left hindlimb of shivering vs. control horses was a significantly higher peak EMG activity of VL ($P = 0.008$) in shivering horses during forward walking. For this reason, we focused our presented figures on the right hindlimb.

Locomotor exam

No abnormalities were noted during the locomotor exam of the control horses with scores of 0 for all phases/gaits. Five of the horses with shivering were classified as having shivers-hyperflexion and two shivers-hyperextension (S5, S7) according to Draper *et al.* [3].

Standing: The median locomotor score for shivering horses was 1 (range: 0–6) (max possible score = 9). Five of the seven shivering horses intermittently held a hindlimb hyperflexed.

Leg Lift: The median locomotor score was 6 (4–11) (max = 12). Six of the seven shivering horses initially resisted lifting the hindlimbs but with effort the limb could be forced to flex and four horses then held the limb hyperflexed.

Backward: The median locomotor score was 7 (1–12) (max = 12). None of the shivering horses had a smooth sequence of contralateral fore and hindlimb movement. Six shivering horses resisted backward walking and two horses showed marked agitation swinging their head at the handler. Three shivering horses showed protracted hyperflexion of one or both hindlimbs and two showed rigidity and hyperextension of the hind and fore limbs.

Forward walking and trotting: The median locomotor score for forward walking was 1 (0–3) and for trotting 0 (0–2) (max = 12). During forward walking, two shivering horses showed mild to moderate intermittent hyperflexion of a hindlimb, and during trotting, one horse had a very low hoof arc in the swing phase of both walking and trotting. Complete clinical scores are provided in Table 2.

Correlation of sEMG and locomotor exam scores: BF and VL were used to compute correlations since data for TFL and EDL was incomplete for one horse and EDL data for the left hindlimb was incomplete for a second horse (electrodes/wires pulled off during data collection trials). Total locomotor exam scores correlated with the mean peak EMG (combined BF and VL) ($r = 0.87$; P-value <0.0001) and iEMG (combined BF and VL) ($r = 0.87$; P-value <0.0001) activity during backward walking (Fig 5).

Neuropathology

Subjective visual inspection of the cerebellum identified one shivering horse (S4) that appeared to have gross atrophy of the cerebellar folia (Fig 6a); however, this was subjective and cerebellum: whole brain ratios were not evaluated. Gliosis was evident in HE stains of the DCN region of this horse. Axonal degeneration was not readily apparent in HE stains of the DCN of shivering horses with a median and range of spheroids/section of: 2.0 (0–4) right DCN and 1.5 (0–6) left DCN. Calbindin stains, which assist in identifying Purkinje cells, revealed numerous positively stained spheroids

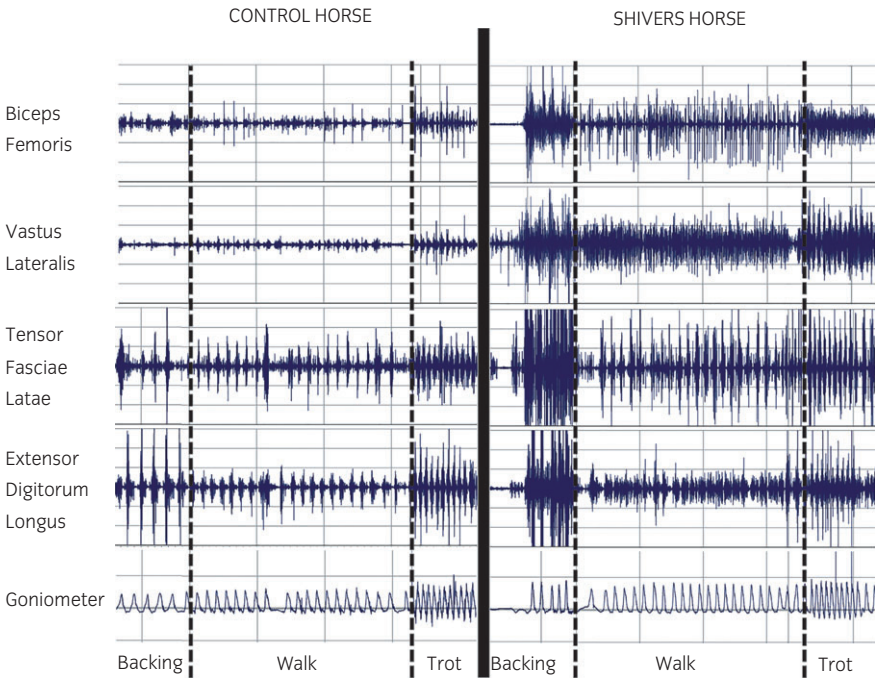

Fig 2: Sample sEMG and goniometer recordings representing traces for all four muscles of the right hindlimb of a control horse and shivering horse (S1). Traces are separated by a dashed black line into sections according to gait (walking backward, walking forward and trotting). Thin grey vertical lines represent a 10 s duration.

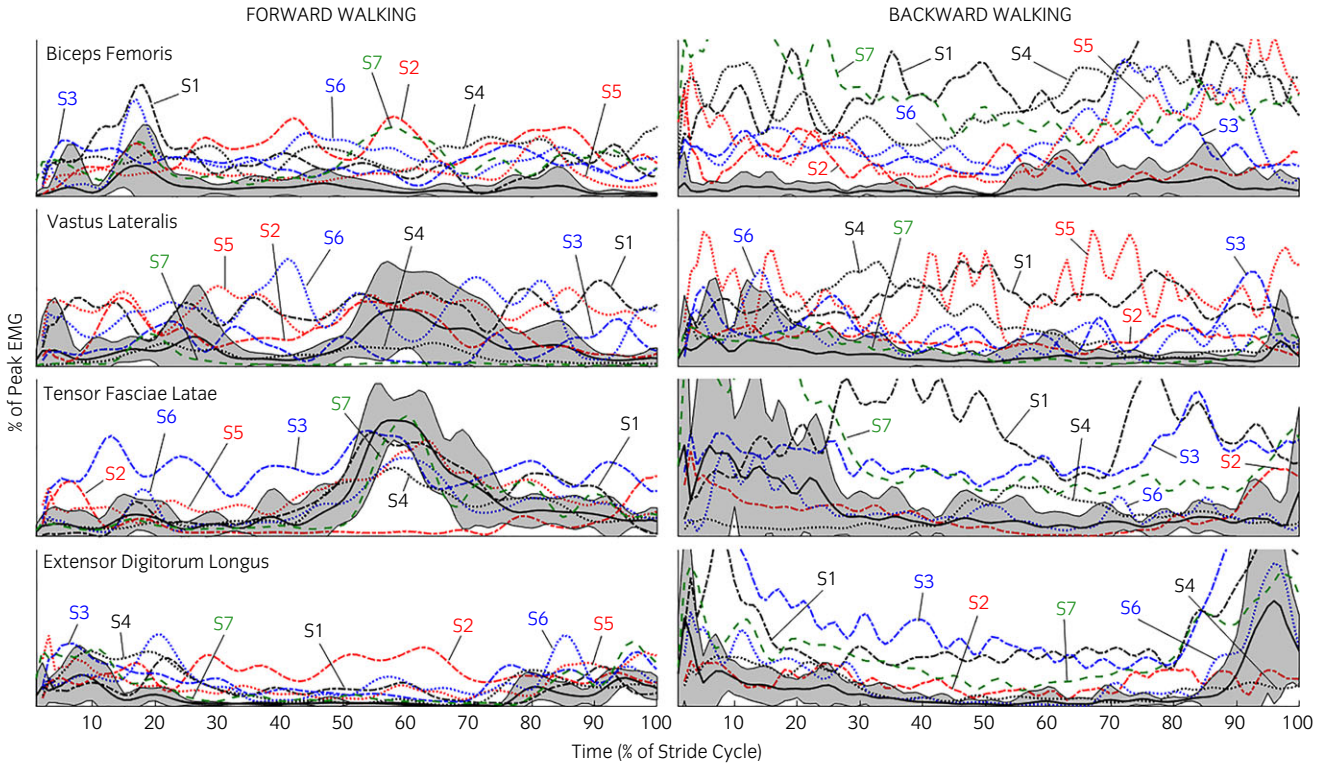

Fig 3: EMG ensembles for each muscle recorded from the right leg during walking forward and backward. Ensembles are plotted as normalised sEMG – relative to peak trotting sEMG – across a normalised stride cycle (0–100% – hoof strike to subsequent hoof strike). Mean sEMG activity for each respective muscle of control horses is represented across the entire stride as an average (solid black line) and the shaded grey area indicates ±2 standard deviations (s.d.). Shivering horses are represented with individual means (various dashed lines).

TABLE 1: Mean (s.d.) peak and integrated EMG activity across muscles of the right and left hindlimbs in control horses and horses with shivering

GAIT	Control Right hind	Shivering Right hind	Control Left hind	Shivering Left hind
Peak EMG (%)				
Trotting	76.1 ± 3.4[a]	81.4 ± 4.8[a]	73.4 ± 3.4[a]	79.8 ± 2.2[a]
Backward	47.5 ± 21.9[b]	88.5 ± 21.5[a £]	57.4 ± 20.0[a,b]	74.5 ± 13.8[a]
Forward	36.9 ± 15.7[b]	49.2 ± 8.9[b]	45.8 ± 23.2[b]	52.0 ± 10.6[b]
Control vs. shivering all gaits		*P<0.0001		*P<0.0098
iEMG				
Trotting	33.92 ± 4.7[a]	40.3 ± 3.1[a]	35.3 ± 6.1[a]	40.3 ± 3.0[a]
Backward	14.0 ± 2.9[b]	37.9 ± 8.4[a £]	19.1 ± 5.0[b]	32.8 ± 7.5[a £]
Forward	13.4 ± 4.4[b]	21.9 ± 3.7[b]	16.7 ± 7.7[b]	23.6 ± 5.1[b]
Control vs. shivering all gaits		*P<0.0001		*P<0.0001

Data for the right hind of shivering horses was analysed with Kruskal–Wallis tests (not normally distributed) and for the left hind two-way ANOVA with Bonferroni pairwise post hoc testing. P values are given for differences between control and shivering horses for all gaits combined. Within gaits, significant differences *between shivering and control horses* is indicated by [£]. Values with differing superscripts ([a,b]) indicate significant differences between gaits within control horses and, likewise, significant differences between gaits within shivering horses.

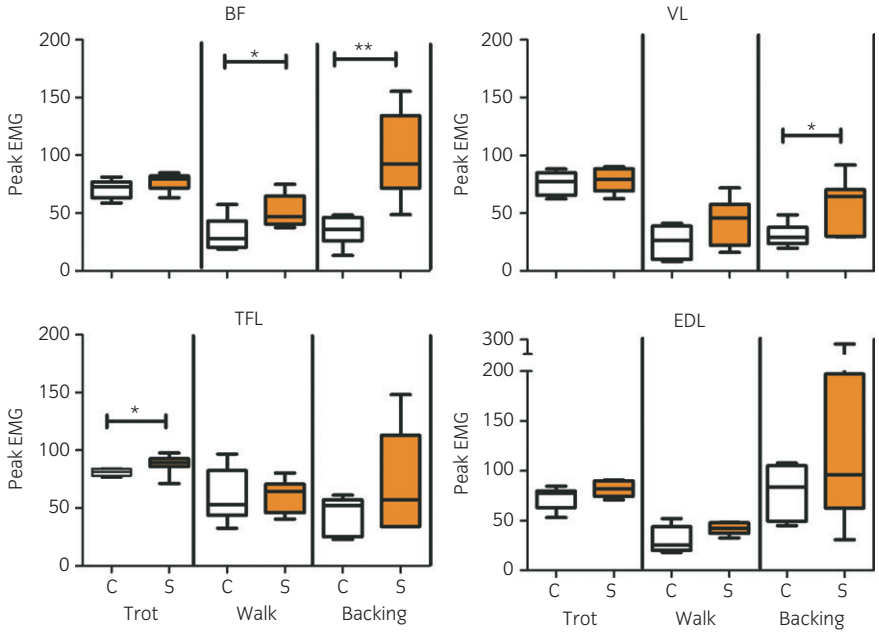

Fig 4: Box and whiskers plots with median, minimum and maximum values for the amplitude of mean peak EMG for each muscle of the right hindlimb during trotting, walking forward, and walking backward in the control horses (white) and horses with shivering (orange). Asterisks indicates a significant difference (*P<0.05, **P<0.001).

in the left or right DCN of all horses with shivering that were examined (Table 2, Fig 6b). Mean counts for the right deep cerebellar nuclei were 158 (range 0 to >400) and for the left 161 (range 21 to >400) which is much greater than the 1–5 calbindin positive spheroids/section reported previously in three healthy control horses [7].

Discussion

This study provides new insights into the pathophysiological mechanism of the disease shivering. Through a systematic examination of muscle activation, we determined, for the first time, that the recruitment patterns of hindlimb muscles in horses with shivering are characterised by sustained, elevated levels of activation and a loss of the temporal modulation and precise firing patterns that are the hallmarks of a coordinated and controlled gait [6,7]. Control horses matched for breed and size showed the typical recruitment patterns reported in previous literature of sEMG recordings of equine locomotion [6,7]. In general, control horses had highly repeatable temporal firing patterns of muscles during the stride cycle. In contrast, shivering horses exhibited large variation in temporal activity making it difficult to identify concise firing patterns in individual muscles. Abnormal motor unit recruitment activity in horses with shivering occurred throughout the stride cycle particularly during walking backward and patterns of temporal modulation were either absent or masked by the uncontrolled co-contraction of flexor and extensor muscles, showing disordered bursting periods and/or continuous tonic activity throughout the stride (Fig 2). The four muscles used for sEMG in this study were selected based on their flexor and extensor functions in relation to the frequently exhibited distinctive posture of hip extension and marked stifle and hock flexion seen in many horses with shivering [3]. The strong co-contraction of the BF (hip extensor, stifle flexor and/or extensor) simultaneous with the VL (hip flexor, stifle extensor) during backward walking is consistent with the clinical signs of a fixed hyperflexed or hyperextended hindlimb posture of shivering horses.

TABLE 2: Clinical locomotor exam scores and calbindin-positive spheroid count for the seven horses with shivering

	Locomotor test scores						Calbindin+ spheroids	
ID	Stance	Leg lift	Walking backward	Walking forward	Trot	Total score	Left DCN	Right DCN
Max score	9	12	12	12	12	57		
S1	6	11	10	0	0	27	183	98
S2	1	4	3	1	0	9	120	0
S3	3	7	5	3	0	18	33	0
S4	1	6	7	2	2	18	400	400
S5	0	6	12	1	0	19	21	400
S6	2	4	1	2	0	9	210	48
S7	0	9	9	1	0	19	ND	ND
Mean	1.9	6.7	6.7	1.4	0.3	17	161	158
Median	1	6	7	1	0	18	152	73
Range	0–6	4–11	1–12	0–3	0–2	9–27	21–400	0–400

Horses were scored for each part of the locomotor exam using the criteria; 0 = normal, 1 = mildly abnormal, 2 = moderately abnormal and 3 = markedly abnormal. Stance was scored for willingness to stand and for spontaneous hyperflexion of each hindlimb. During leg lift and at each gait, horses were scored for reluctance to perform the movement, the degree of coordination of the movement between fore- and hindlimbs and for each hindlimb, abnormal hyperextension or hyperflexion. The total number of calbindin positive spheroids present in the left and right sections of the deep cerebellar nuclei (DCN) are indicated for each horse. ND = not done.

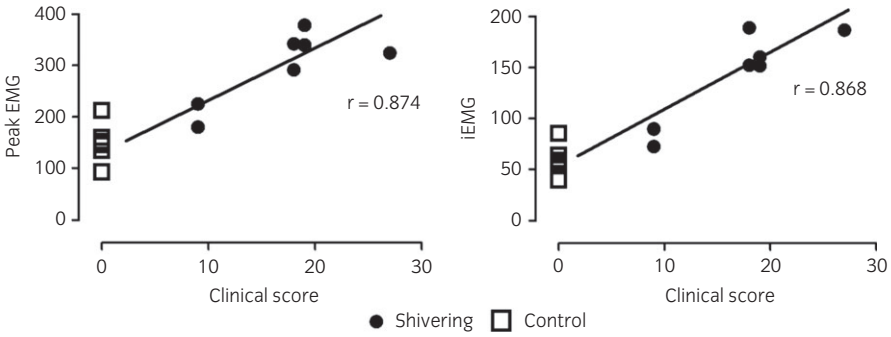

Fig 5: Plot of clinical score vs. peak and iEMG activity (combined BF and VL). A significant correlation was found in shivering horses between sEMG activity during walking backward and the severity of shivering as represented by the total clinical locomotor score. Control horses (square), are shown for comparison in peak and iEMG activity.

The clinical locomotor score of horses with shivering showed a significant correlation with iEMG and peak EMG of BF and VL muscles during walking backward, further strengthening the conclusion that clinical signs of shivering are due to abnormal and simultaneous firing of hindlimb flexor and extensor muscles. It is of note, however, that the clinical evaluation largely detected abnormalities in horses with shivering during backward but not forward gaits, whereas measures of peak EMG and iEMG detected abnormal muscle activation during forward (and backward) walking and trotting in shivering horses with each muscle showing elevated levels of normalised sEMG activation while at the same time exhibiting altered (or masked) concise firing patterns during specific phases of the stride cycle (Fig 3, Supplementary Items 2 and 3). The indication of altered firing patterns during walking forward seen in our data indicate that although clinical signs may not appear to be present during walking forward in shivering horses, abnormalities in motor unit recruitment are indeed present.

This study provides a link between abnormal sEMG patterns in shivering horses and cerebellar Purkinje cell dysfunction. While the number of shivering horses examined was limited and, therefore, may not be representative of the entire population, the abnormal sEMG activity accompanied by numerous calbindin-positive spheroids in the lateral DCN presented in our data, is compelling. The first evidence of selective distal axonal degeneration in cerebellar Purkinje cells in horses with shivering was provided by a recent extensive neuropathological study [8]. When compared with controls, calretinin-negative, calbindin-positive and the number of glutamic acid decarboxylase-positive spheroids were increased 80-fold in Purkinje cell axons within the DCN of horses with shivering compared with controls [8]. This was the only region of the central nervous system that had a statistically significant difference in number of axonal spheroids between control and shivering horses. Furthermore, the numbers of end terminal synapses within the DCN appeared to be reduced with degeneration being most evident in the lateral nuclei (dentate and interpositus). Given the findings of the study by Valberg *et al.* (2015), we evaluated only the region of the DCN with HE and calbindin stains [8], which is a potential limitation of this study. Another limitation of the current study is that control horses were not subjected to euthanasia to evaluate the DCN and thus comparisons are made with a limited number of control horses from a previous study. In direct agreement with the previous study, however, numerous calbindin-positive spheroids were identified in the lateral DCN of the horses with shivering, localising axonal degeneration to Purkinje cells. Axons of Purkinje cells are the sole efferent output from the cerebellum and their pattern of connections in the DCN roughly maintains the temporal and spatial features conserved within the cerebellum itself [12]. However, because our neuropathological examination focused specifically on the DCN, we cannot fully exclude additional lesions that may have influenced the abnormal sEMG findings in shivering horses. Conversely, the presumed distal axonal degeneration, when severe, may be expected to result in Purkinje cell chromatolysis, or other evidence of degeneration, none of which could be detected [8].

The cerebellum plays a major role in the control of gait, posture and the coordination of multijoint limb movements [13]. The medial cerebellar zone regulates postural muscle tone during locomotion [14–17]. Isolated lesions in one of the lateral DCN in quadrupeds, the nucleus interpositus, has been shown to result in prolonged extension [18] and hyperflexed movements during locomotion, leading to a prolonged swing phase and shortened

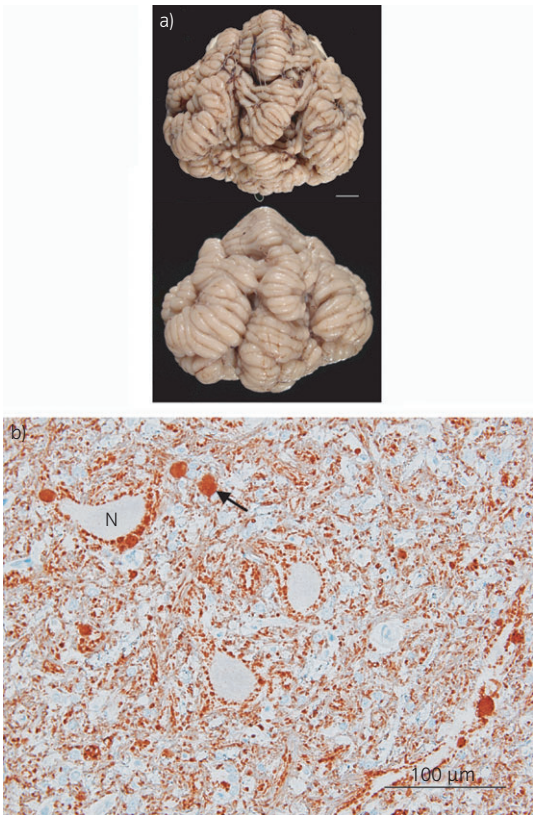

Fig 6: a) Gross atrophy of the cerebellar folia in one of the shivering horses (S4) (top) is evident when compared with a normal horse cerebellum (bottom). b) The lateral nucleus of the deep cerebellar nuclei of shivering horse S4 showing calbindin-positive spheroids within distal Purkinje cell axons in the neuropil (arrow) or surrounding neuronal cell bodies (N).

stance phase [19], hypertonia, rigidity and a loss of tactile placing responses [20]. Stimulation of the nucleus dentatus and nucleus interpositus in cebus monkeys elicits postural responses primarily in the proximal antigravity muscles of the limbs [21] and subsequent induction of lesions in these nuclei modified postural tone of these muscles. Furthermore, mice with Purkinje cell degeneration (Lurcher mice) also presented with signs of exaggerated hindlimb flexion in the swing phase, hypertonic extensor activity at the tarsus, irregular reciprocal inhibition of antagonist muscles and increased variability in interlimb coupling during gait [22], consistent with those clinical signs noted in shivering. EMG patterns have been studied in Lurcher mice and similar to horses with shivering, continuous and heightened amplitude of EMG activity and temporal loss of modulation of EMG bursting during locomotion was identified [22].

The preceding studies provide evidence for lesions in the DCN corresponding to the abnormal hindlimb gait of horses with shivering. Thus, one may hypothesise that in equine shivering the reduced or lost inhibitory output via the DCN leads to enhanced excitation of selected efferent targets that modulate muscle tone in response to specific motor actions, such as seen during the locomotor examinations. The clinical signs exhibited by horses with shivering may also be related to the progression of the disease. Lurcher mice were able to walk normally when 60% of the cerebellar Purkinje cells had degenerated [22]. However, locomotor patterns began to deteriorate when approximately 90% of the Purkinje cells had degenerated [22]. A progression of shivering has been indicated in a report by Draper *et al.* [4] and anecdotally by owners of the horses in the present study. Consequently, a progression in clinical signs of shivering may be indicative of progressing Purkinje cell degeneration. It is important to note, however, that other causes of equine cerebellar disease, such as that seen in Arabian foals with cerebellar abiotrophy, do not present with shivering [22,23]. Thus, a full explanation for the role of Purkinje cell degeneration and shivering is still lacking.

It is difficult to explain why muscle recruitment was more severely disrupted during walking backward compared with walking forward in horses with shivering. The focal nature of the lesion in the DCN of shivering horses may offer a partial explanation as to why the horses with shivering often showed minimal clinical abnormalities in their forward gaits. A further possibility is that forward locomotion may be largely an entrained spinal locomotor pattern, whereas taking more than a few steps using backward locomotion is not a natural locomotor response in horses and is potentially associated with a larger cognitive load used when horses cannot see the specific details of terrain during backward compared with forward movement. The cerebellum plays an important role in modulating motor output from the cerebral cortex and thus may play a bigger role in backward vs. forward gaits. Lastly, stress is known to exacerbate signs of shivering [1,4] and may, therefore, contribute to the increased muscle activation as stress and mental agitation can materialise when horses intend to move backward with no sight line but are unable to reliably do so due to coactivation of flexor and extensor muscles. Therefore, increased stress is noteworthy when interpreting the substantial increase in sEMG activation during backward walking. However, also noteworthy was that escalated sEMG amplitudes were seen even when shivering horses were not exhibiting signs of stress.

No attempt was made to correlate the number of spheroids present in shivering horses with the severity of clinical signs in each limb. This is because caution must be used when equating a temporal marker such as spheroid formation with clinical signs. Dysfunction of Purkinje cell axonal transport could well proceed notable spheroid accumulation or alternatively loss of Purkinje cell axons could follow spheroid formation later in the disease course. The stage of clinical disease was not standardised in the horses in this study. Further variability could also be introduced by accuracy in trimming and sectioning of the small region containing the DCN.

In summary, our data provide the first electrophysiological evidence that equine shivering is characterised by enhanced simultaneous recruitment of flexor and extensor muscles and a loss of the ability to modulate motor unit recruitment in the hindlimbs, particularly when walking backward. Abnormal muscle activation in horses with shivering was consistent with the observed hyperflexion or hyperextension of hindlimbs and was associated with the presence of selective Purkinje cell axonal degeneration in DCN.

Authors' declaration of interests

No competing interests have been declared.

Ethical animal research

The University of Minnesota and Michigan State University Institutional Animal Care and Use Committees approved this study. Owners gave consent for their animal's inclusion in the study.

Sources of funding

This study was funded by the University of Minnesota College of Veterinary Medicine Comparative Medicine Signature Program, the United States Equestrian Foundation and the Mary Anne McPhail Dressage Chair Endowment.

Acknowledgements

A special thanks to Dr I-Ling Yeh and other members of the Human Sensorimotor Control Laboratory and those within the University of Minnesota Department of Veterinary Population Medicine. Also a special thanks to Dr Susan Holcombe and the Michigan State University Department of Large Animal Clinical Sciences for their help in completing this project.

Authorship

J. Konczak and S. Valberg developed study design. Execution of EMG recordings was performed by J. Aman, N. Elangovan, A. Nicholson and S. Lewis, locomotor evaluation by S. Valberg. Data analysis was contributed by J. Aman, J. Konczak and S. Valberg. Manuscript first draft was prepared by J. Aman, edited by S. Valberg and J. Konczak and all authors provided final approval of the submitted version of the manuscript.

Manufacturers' addresses

[a]Biometrics Ltd., Newport, UK.
[b]GraphPad Software, Inc., LaJolla, California, USA.

References

1. Baird, J.D., Firshman, A.M. and Valberg, S.J. (2006) Shivers (shivering) in the horse: a review. *Am. Assoc. Equine. Pract. Proc.* **52**, 359-364.
2. Fintl, C. (2003) Idiopathic and rare neurologic diseases. In: *Current Therapy in Equine Medicine*, 3rd edn., Ed: L. Mills, W.B. Saunders Company, Philidelphia. pp. 760-763.
3. Draper, A.C., Trumble, T.N., Firshman, A.M., Baird, J.D., Reed, S., Mayhew, I.G., Mackay, R. and Valberg, S.J. (2015) Posture and movement characteristics of forward and backward walking in horses with shivering and acquired bilateral stringhalt. *Equine Vet. J.* **47**, 175-181.
4. Draper, A.C., Bender, J.B., Firshman, A.M., Baird, J.D., Reed, S., Mayhew, I.G. and Valberg, S.J. (2015) Epidemiology of shivering (shivers) in horses. *Equine Vet. J.* **47**, 182-187.
5. Clayton, H.M. and Schamhardt, H.C. (2000) Measurement techniques for gait analysis. In: *Equine Locomotion*, Eds: W. Back and H.M. Clayton, Clayton, Saunders Ltd, Philadelphia. pp 55-76.
6. Robert, C., Valette, J.P., Degueurce, C. and Denoix, J.M. (1999) Correlation between surface electromyography and kinematics of the hindlimb of horses at trot on a treadmill. *Cells Tissues Organs* **165**, 113-122.
7. Robert, C., Valette, J.P. and Denoix, J.M. (2000) The effects of treadmill inclination and speed on the activity of two hindlimb muscles in the trotting horse. *Equine Vet. J.* **32**, 312-317.
8. Valberg, S.J., Lewis, S.S., Shivers, J.L., Barnes, N.E., Konczak, J., Draper, A.C. and Armien, A.G. (2015) The equine movement disorder "Shivers" is associated with selective cerebellar purkinje cell axonal degeneration. *Vet. Pathol.* **52**, 1078-1098.
9. Vilis, T. and Hore, J. (1977) Effects of changes in mechanical state of limb on cerebellar intention tremor. *J. Neurophysiol.* **40**, 1214-1224.
10. De Luca, C.J., Gilmore, L.D., Kuznetsov, M. and Roy, S.H. (2010) Filtering the surface EMG signal: movement artifact and baseline noise contamination. *J. Biomech.* **43**, 1573-1579.
11. Nakamura, R., Kurita, K., Kawanami, T. and Kato, T. (1999) An immunohistochemical study of Purkinje cells in a case of hereditary cerebellar cortical atrophy. *Acta Neuropathol.* **97**, 196-200.
12. Grimaldi, G. and Manto, M. (2012) Topography of cerebellar deficits in humans. *Cerebellum* **11**, 336-351.
13. Thach, W.T., Goodkin, H.P. and Keating, J.G. (1992) The cerebellum and the adaptive coordination of movement. *Annu. Rev. Neurosci.* **15**, 403-442.
14. Imperato, A., Nicoletti, F., Diana, M., Scapagnini, U. and Di Chiara, G. (1984) Fastigial influences on postural tonus as studied by kainate lesions and by local infusion of GABAergic drugs in the rat. *Brain Res.* **295**, 51-63.
15. Iwakiri, H., Oka, T. and Mori, S. (1994) Multi-segmental and generalized suppression of postural muscle tone evoked by stimulating the dorsal tegmental field and the medial pontine reticular formation in acute decerebrate cats. *Neurosci. Lett.* **182**, 83-86.
16. Mori, S., Matsui, T., Kuze, B., Asanome, M., Nakajima, K. and Matsuyama, K. (1998) Cerebellar-induced locomotion: reticulospinal control of spinal rhythm generating mechanism in cats. *Ann. N. Y. Acad. Sci.* **860**, 94-105.
17. Mori, S., Matsui, T., Kuze, B., Asanome, M., Nakajima, K. and Matsuyama, K. (1999) Stimulation of a restricted region in the midline cerebellar white matter evokes coordinated quadrupedal locomotion in the decerebrate cat. *J. Neurophysiol.* **82**, 290-300.
18. Thach, W.T., Kane, S.A., Mink, J.W. and Goodkin, H.P. (1992) Cerebellar output: multiple maps and modes of control in movement coordination. In: *The Cerebellum Revisited*, Eds: R., Llin´s and C., Sotelo, Springer-Verlag, New York. pp 283-300.
19. Udo, M., Matsukawa, K., Kamei, H. and Oda, Y. (1980) Cerebellar control of locomotion: effects of cooling cerebellar intermediate cortex in high decerebrate and awake walking cats. *J. Neurophysiol.* **44**, 119-134.
20. Dow, R.S. and Moruzzi, G. (1958) *The Physiology and Pathology of the Cerebellum*, University of Minnesota Press, Minneapolis.
21. Schultz, W., Montgomery, E.B. Jr and Marini, R. (1979) Proximal limb movements in response to microstimulation of primate dentate and interpositus nuclei mediated by brain-stem structures. *Brain* **102**, 127-146.
22. Fortier, P.A., Smith, A.M. and Rossignol, S. (1987) Locomotor deficits in the mutant mouse, Lurcher. *Exp. Brain Res.* **66**, 271-286.
23. Mayhew, I.G. (2008) *Large Animal Neurology*, 2nd edn., Wiley-Blackwell Pub., Chichester, U.K.; Ames, Iowa. pp viii, 453 pages.

Supporting Information

Additional Supporting Information may be found in the online version of this article at the publisher's website:

Supplementary Item 1: Surface EMG set-up, measurement and analysis.
Supplementary Item 2: sEMG ensembles: backward walking.
Supplementary Item 3: sEMG ensembles: forward walking.
Supplementary Item 4: Integrated EMG vs. Peak EMG.